

The Value of Shear Wave Elastography and Velocity Standard Deviation Value in the Differentiation of Subacute Thyroiditis and Chronic Autoimmune Thyroiditis

Deniz Esin Tekcan Şanlı^{1,2}, Düzgün Yıldırım³

¹Department of Medical Imaging Techniques, İstanbul Rumeli University, Vocational School of Health Services, İstanbul, Turkey

²Department of Radiology, Acıbadem Kozyatağı Hospital, İstanbul, Turkey

³Department of Medical Imaging Techniques, Acıbadem University, Vocational School of Health, İstanbul, Turkey

Cite this article as: Tekcan Şanlı DE, Yıldırım D. The value of shear wave elastography and velocity standard deviation value in the differentiation of subacute thyroiditis and chronic autoimmune thyroiditis. *Cerrahpaşa Med J.* 2022;46(2):115-120.

Abstract

Objective: To evaluate the possibility of distinguishing between subacute thyroiditis and chronic autoimmune thyroiditis, which can mimic each other in terms of clinical, laboratory, and radiological findings with shear wave elastography.

Methods: Patients who were diagnosed with subacute thyroiditis according to their clinical, laboratory, and radiological characteristics (Group 1) and patients using drugs for chronic autoimmune thyroiditis (Group 2) were included in the study. All patients underwent shear wave elastography examination after thyroid ultrasonography. V_{mean} and velocity standard deviation (V_{sd}) values were measured in both lobes with shear wave elastography. Grayscale and Doppler sonography imaging features of the patients (parenchymal heterogeneity, perithyroidal lymph node, parenchymal vascularity) and laboratory values (TSH, anti-thyroid peroxidase antibody, anti-thyroglobulin) were recorded. It was evaluated statistically whether there was a significant difference between the groups in terms of these parameters and shear wave elastography values.

Results: Although there was no significant difference between the groups in terms of clinical, laboratory, and radiological features, the total thyroid gland volume was higher in Group 1. The rate of parenchymal heterogeneity and hypovascularity was higher in Group 1. No significant difference was found in terms of elastographic parameters. The elastographic stiffness was higher in Group 1 than in Group 2 for both lobes.

Conclusion: In the presence of hypovascular heterogeneous patchy areas with increased thyroid gland sizes, it is more possible to support the diagnosis of subacute thyroiditis by ultrasonography. The V_{sd} value of 0.4 and above with elastography strengthens the diagnosis in terms of subacute thyroiditis.

Keywords: Anti-TPO, chronic autoimmune thyroiditis, shear wave elastography, subacute thyroiditis, velocity, V_{sd}

Introduction

Diffuse parenchymal thyroid diseases (DPTD) are one of the most common diseases of the thyroid gland. Subacute thyroiditis (SAT) is a self-limiting clinical condition that usually develops after a latent period after an upper respiratory tract infection, secondary to an autoimmune response. Painful thyroid gland on palpation is the most important symptom of the disease.^{1,2} Although thyroid function tests may vary according to the degree of damage, transient thyrotoxicosis is usually seen.^{1,2} Values such as erythrocyte sedimentation rate (ESR) and C-reactive protein (CRP) associated with acute inflammation are significantly higher. The presence of ill-defined patchy, heterogeneous, hypovascular, hypoechoic areas on grayscale examination greatly supports the diagnosis, and most findings resolve almost completely within a few weeks after treatment.^{1,2} On the other hand, in chronic autoimmune thyroiditis (CAT), grayscale image findings may vary widely according to the stage of the disease. It may be completely normal, or a heterogeneous and coarsened echostructure with a pseudonodular appearance with

increased or decreased gland size may be observed. Gland vascularity may also be increased, decreased, or normal depending on the stage of the disease.³ The presence of accompanying parathyroidal lymph nodes supports the diagnosis sonographically.⁴ The presence of autoantibodies such as anti-thyroglobulin antibody (anti-Tg) and anti-thyroid peroxidase antibody (anti-TPO) is an important laboratory parameter in the diagnosis of CAT.⁵ Most of the diffuse parenchymal thyroid diseases may mimic each other in terms of etiology, clinical, laboratory, and radiological findings. This situation may cause clinicians and radiologists to have difficulties in diagnosis. For example, diffuse increased vascularity in Doppler sonography can be seen in Graves' disease (GD) as well as in the acute exacerbation phase of CAT. However, some traits tend to be more dominant in others. For example, while severe neck-throat pain on palpation is the clinical feature of acute and SAT, pseudonodular appearance with echogenic fibrotic septations on ultrasonographic examination is mostly seen in CAT, or patchy, heterogeneous, hypovascular, hypoechoic areas are more common in SAT.⁶

Elastography has recently become a frequently used method in the evaluation of thyroid diseases. There are a number of studies showing the effectiveness of elastography in the radiological distinction of DPTD. In this study, we aimed to investigate the diagnostic efficiency of shear wave elastography (SWE) and velocity in SAT and CAT cases by evaluating laboratory values, grayscale, and elastography features.

Received: October 18, 2021 Accepted: December 1, 2021

Corresponding author: Deniz Esin Tekcan Şanlı, Department of Medical Imaging Techniques, İstanbul Rumeli University, Vocational School of Health Services, İstanbul, Turkey

e-mail: tekcanzenizesin@gmail.com

DOI: 10.5152/cjm.2022.21094



Methods

Study Population

This prospective study included cases who underwent thyroid ultrasonography in our clinic in 2021. The cases were divided into 2 groups as Group 1 (diagnosed with SAT) and Group 2 (diagnosed with CAT). The diagnosis of SAT was made according to the physical examination (painful goiter), laboratory parameters (elevated ESR and CRP), fever, and typical appearance on ultrasonography (ill-defined, heterogeneous, hypovascular, hypoechoic, patchy areas) (Figure 1).^{6,7} The diagnosis of CAT was made on high anti-TPO and anti-Tg antibody levels, high TSH levels, and imaging findings in symptomatic patients.⁸ None of the patients in our study had a histopathological diagnosis (Figure 2).

Group 1 consisted of patients who underwent ultrasonographic examination at the time of the first admission to the hospital and at the third month after admission and who had a significant clinical, laboratory, and radiological regression at the third month follow-up.⁶ Only the ultrasonography and SWE images of these Group 1 patients at the first time of admission were evaluated in the study.

Patients with a diagnosis of or suspected GD, patients with thyroid nodules, those who received radiotherapy to the neck region or had an operation in the neck region, and those with connective tissue disease were excluded from the study.

Ethics committee approval dated June 9, 2021, numbered 2021-10/08 was obtained from the university of our hospital for the study. Informed consent was obtained from all individual participants included in the study.

Laboratory Parameters

TSH and anti-thyroid autoantibodies (anti-TPO and anti-Tg), CRP, and ESR values were measured in all subjects in both groups.

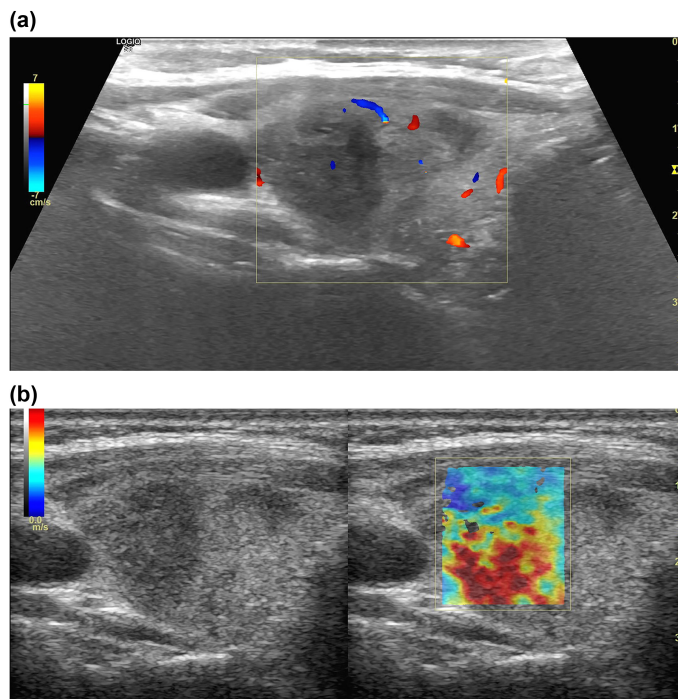


Figure 1. (A) In a case with a diagnosis of subacute thyroiditis, in the lateral part of the right lobe of the thyroid gland, color Doppler sonography shows a hypovascularized, patchy, heterogeneous, hypoechoic area. (B) In shear wave elastography evaluation, markedly increased velocity values and hard color coding (red) are observed in the area.

Conventional (Grayscale and Doppler) Ultrasonography Evaluation

In all of the cases, all ultrasonography and elastography imagings were performed using a LOGIQ S8 (GE Health Care, XDClear 2.0+ Ultrasound System, Wauwatosa, WI, USA) device by a single radiologist with more than 10 years of experience in head and neck imaging (DETS). M6-15 probes were used for grayscale evaluation and 9L probes were used for elastography. Thyroid gland total volume (right lobe+left lobe), parenchymal heterogeneity,⁹ and presence of peri-parathyroidal lymph node were evaluated with grayscale imaging. The volume of each lobe was calculated automatically by the device after measurement in 3 planes (TR × AP × CC). Gland vascularization (increased–normal–decreased) was evaluated by Doppler sonography.¹⁰ The radiologist was blinded in terms of the clinical and laboratory findings.

Shear Wave Elastography Evaluation

All elastographic evaluations were made in the transverse plane. When a clear image could not be obtained, measurements were made in the sagittal plane. During elastography, a gel pad was placed, and cases were asked to hold breath during the SWE measurement. The window was frozen when the most homogeneous image without artifacts was obtained. Measurements were made by manually inserted Region of interest (ROI) from the most prominent parenchyma area reflecting CAT and from the most heterogeneous, hypoechoic area reflecting SAT. The ROI was made large to cover the entire heterogeneous area within the sample box. Stiffness was measured in m/s as V_{mean} and velocity standard deviation (V_{sd}) from each thyroid lobe.

Statistical Analysis

Number Cruncher Statistical System program was used for statistical analysis. Descriptive statistical methods (mean, SD, median, frequency, percentage, minimum, and maximum) were used while evaluating the study data. The conformity of the quantitative data to the normal distribution was tested with the Shapiro–Wilk test and graphical examinations. Student's *t* test was used for comparisons between 2 groups of normally distributed quantitative variables, and Mann–Whitney *U* test was used for comparisons between 2 groups of non-normally distributed quantitative variables. Pearson's chi-square test, Fisher's exact test, and Fisher–Freeman–Halton test were used to compare qualitative data. Statistical significance was accepted as $P < .05$.

Results

A total of 35 cases, 26 females and 9 males, were included in the study. In total, 15 cases in Group 1 and 20 cases in Group 2 were evaluated. The mean age of all cases was 41.06 ± 11.67 (25–67).

Age and gender distribution did not differ significantly between the groups ($P > .05$).

There was no significant difference between the groups in terms of total thyroid gland volumes, parenchymal heterogeneity, and lymph node presence on grayscale imaging and gland vascularity in Doppler sonography ($P > .05$). However, the presence of parenchymal heterogeneity and hypovascular area was higher in Group 1 (Table 1).

Although TSH, anti-TPO and anti-Tg values were not significantly different according to the groups ($P > .05$), anti-TPO values in Group 1 and anti-Tg values in Group 2 were relatively higher (Table 1). Laboratory measurements of all patients were made before ultrasonographic examination. The mean interval between laboratory measurement and ultrasonographic examination was 3.26 ± 1.62 (1–7) days.

There was no statistically significant difference between the groups in terms of right and left V_{mean} and V_{sd} distributions of the

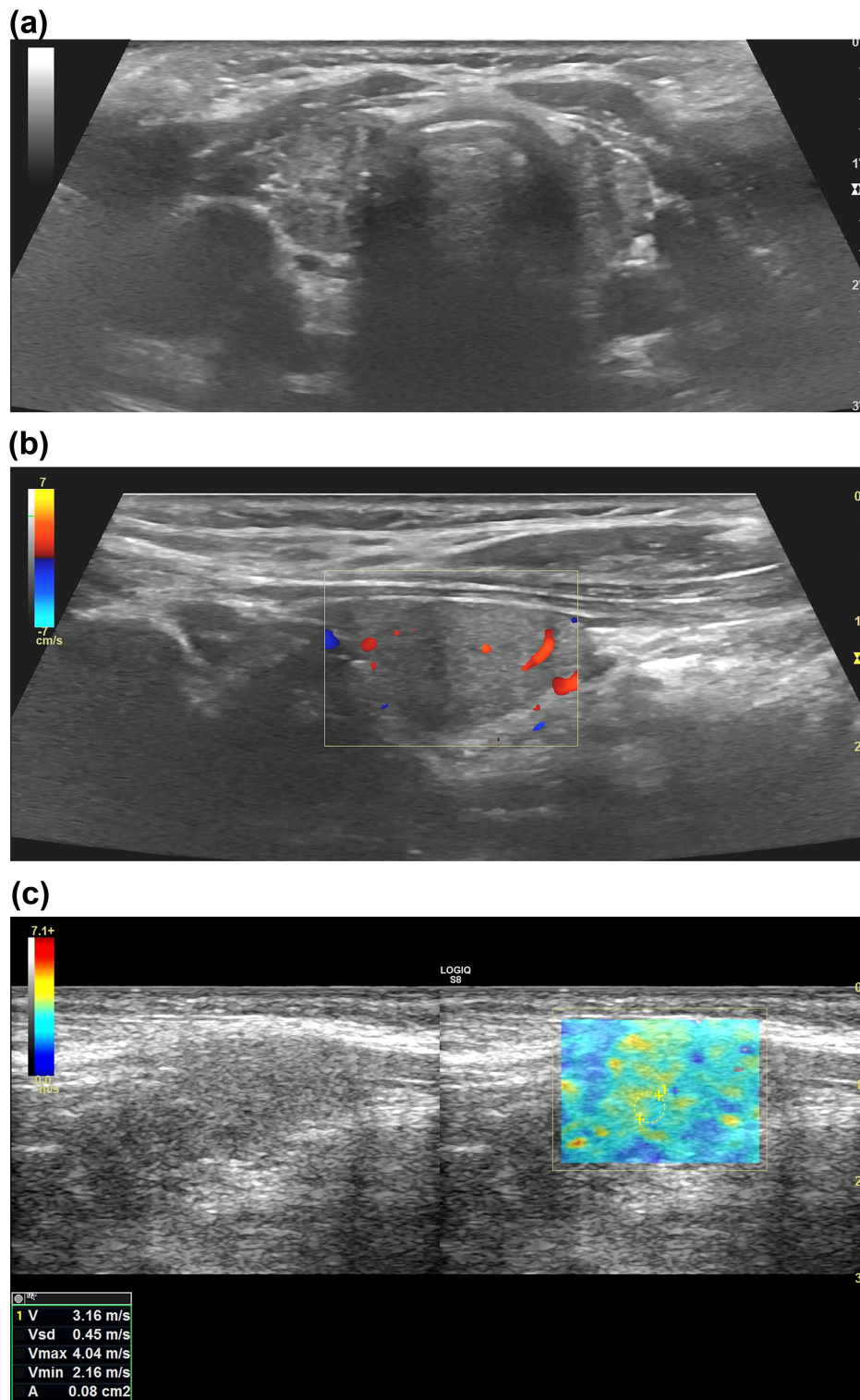


Figure 2. (A) In a case with a diagnosis of chronic autoimmune thyroiditis, decreased thyroid gland volume, contour lobulation, and parenchymal heterogeneity, (B) decreased parenchymal blood supply in color Doppler sonography, and (C) heterogeneous color coding with intermediate stiffness in the parenchyma in shear wave elastography evaluation are seen.

cases ($P > .05$). However, all values in both lobes were higher in Group 1 than in Group 2 (Table 1).

Discussion

Although elastography is frequently used in the differentiation of malignant and benign thyroid nodules, it is also successful in

the evaluation of parenchymal thyroid diseases. Especially in CAT cases, elastographic values are significantly higher than normal people, and elastographic stiffness secondary to parenchymal fibrosis also increases.^{3,11-13} Furthermore, Yang et al¹⁴ showed different values of parenchymal stiffness in different diffuse thyroid diseases. Thus, in the differentiation of diffuse parenchymal

Table 1. Comparisons by groups

		Total	Group 1 (n = 15)	Group 2 (n = 20)	P	
Age	Mean ± SD	41.06 ± 11.67	41.47 ± 11.24	40.75 ± 12.27	.860^a	
	Median (Min-Max)	40 (25-67)	38 (27-65)	40.5 (25-67)		
Gender	Female	26 (74.3)	11 (73.3)	15 (75.0)	1.000^b	
	Male	9 (25.7)	4 (26.7)	5 (25.0)		
Total thyroid gland volume	Mean ± SD	8.93 ± 4.95	10.58 ± 5.99	7.69 ± 3.68	.147^c	
	Median (Min-Max)	7.4 (3.2-23)	10 (3.2-23)	6.5 (3.5-17)		
Gland vascularity	Decreased	27 (77.1)	14 (93.3)	13 (65.0)	.143^d	
	Normal	7 (20.0)	1 (6.7)	6 (30.0)		
	Increased	1 (2.9)	0 (0.0)	1 (5.0)		
Heterogeneity with gray scale	No	15 (42.9)	4 (26.7)	11 (55.0)	.094^e	
	Yes	20 (57.1)	11 (73.3)	9 (45.0)		
Lymph node	No	14 (40.0)	6 (40.0)	8 (40.0)	1.000^e	
	Yes	21 (60.0)	9 (60.0)	12 (60.0)		
Right V	Mean ± SD	2.43 ± 0.99	2.80 ± 1.39	2.16 ± 0.42	.105^a	
	Median (Min-Max)	2.1 (1.2-5.7)	2.6 (1.4-5.7)	2.1 (1.2-3.1)		
Right V	Mean ± SD	0.42 ± 0.40	0.61 ± 0.53	0.28 ± 0.12	.099^c	
	Median (Min-Max)	0.2 (0.1-1.6)	0.2 (0.1-1.6)	0.2 (0.1-0.6)		
Left V	Mean ± SD	2.39 ± 0.86	2.61 ± 1.27	2.22 ± 0.28	.657^c	
	Median (Min-Max)	2.2 (1.4-5.04)	2.02 (1.4-5.04)	2.2 (1.7-2.7)		
Left V	Mean ± SD	0.35 ± 0.29	0.48 ± 0.40	0.25 ± 0.12	.064^c	
	Median (Min-Max)	0.2 (0.1-1.3)	0.2 (0.2-1.3)	0.2 (0.1-0.5)		
Anti-TPO (IU/mL)	Mean ± SD	289.02 ± 488.83	392.31 ± 613.17	195.11 ± 345.20	.863^c	
	Median (Min-Max)	40.9 (10-1500)	34.5 (10-1500)	50.2 (15-1182)		
	<28	8 (38.1)	4 (40.0)	4 (36.4)		1.000^b
	>28	13 (61.9)	6 (60.0)	7 (63.6)		
Anti-Tg (IU/mL)	Mean ± SD	56.44 ± 83.34	37.46 ± 50.46	94.40 ± 129	.570^c	
	Median (Min-Max)	22.8 (1.3-284)	10.4 (1.3-123)	46.1 (1.3-284)		
TSH (uIU/mL)	Mean ± SD	2.39 ± 1.53	2.66 ± 1.90	2.15 ± 1.15	.374^a	
	Median (Min-Max)	1.9 (0-5.4)	2.9 (0-5.4)	1.8 (0.3-4.9)		

^aStudent's t test; ^bFisher's exact test; ^cMann-Whitney U test; ^dFisher Freeman Halton test; ^ePearson chi-square Test

thyroid diseases, elastographic features were started to be used in addition to grayscale features.¹⁵ They showed that the positive predictive value of grayscale ultrasonography alone in the diagnosis of SAT was 79.4%.⁷ It can be thought that the diagnostic value increases when combined with elastography compared to ultrasonography alone.³ We have noticed in our study that although the damage at the cellular level has not yet been reflected in the grayscale appearance as parenchymal heterogeneity, heterogeneous color coding can be observed in elastography, especially in early disease periods when the parenchyma is observed normally in grayscale. That is, elastographic image features can become

heterogeneous before the grayscale. This may contribute to the diagnosis in patients with chronic thyroiditis whose parenchyma appears normal with grayscale.

According to the Kara et al study,¹⁶ 29.45 kPa or 2.77 m/s was found as a sensitive-specific cut-off value for CAT. Hekimoglu et al³ determined that the mean elastography value for CAT patients was 2.56 ± 0.30 m/s and the cut-off was 2.42 m/s. Ruchala et al⁶ found that the baseline thyroid stiffness in SAT (214 kPa) was higher than that found in CAT (36 kPa) and control group (16 kPa). In our study, mean V_{mean} values in CAT cases were 2.16 m/s in the right lobe and 2.22 m/s in the left lobe, and lower values were obtained for

CAT group compared to other studies. However, the V_{mean} values in both lobes in SAT cases were higher than those in the CAT group (right: 2.80 m/s, left: 2.61 m/s). It is thought that the reason for this is that all the patients in our study group were under L-thyroxine treatment and that the treatment might have an effect on parenchymal stiffness. Or, it may be thought that patients in other studies had a longer diagnosis of CAT. Because in CAT, elastographic stiffness and velocity values increase in proportion to the duration of the disease and fibrosis.^{16,17}

Korkmaz et al¹⁸ showed in their study that strain elastography was effective in distinguishing SAT from other thyroiditis; however, elastography was limited in distinguishing SAT-GD and CAT-GD.¹⁸ Similarly, Liu et al¹⁷ showed that elastography was not effective in CAT-GD and SAT-GD discrimination. Since we excluded GD patients in our study, we could not evaluate this situation. However, we could not detect a significant difference in terms of laboratory–radiological–elastographic characteristics in the SAT–CAT distinction. We think that the reason for this is the low number of patients in both groups. Consistent with the literature, enlargement in gland sizes and the presence of heterogeneous–hypovascular areas was higher in the SAT group in our study. Age, gender, presence of perithyroidal lymph node rates were equal in both groups. In terms of SWE, both V_{mean} and V_{sd} values were found to be higher in the SAT group than in the CAT group. V_{sd} is considered as an SWE parameter that quantitatively reflects parenchymal heterogeneity.¹⁹ The presence of parenchymal heterogeneity is an important indicator of chronic parenchymal thyroid diseases, and heterogeneity can be seen in all of them. Therefore, in our study we wanted to evaluate whether there was a significant difference between the groups in terms of parenchymal heterogeneity, we included V_{sd} values in addition to SWE and V_{mean} values. We obtained higher V_{sd} values in patchy, heterogeneous areas where more diffuse heterogeneity was observed in the SAT group than in the CAT group similar to other studies.⁶

High levels of anti-thyroid antibodies in CAT are very important in diagnosis. Especially, high anti-TPO values strongly support the diagnosis of CAT.²⁰ Anti-thyroglobulin antibodies are mostly high in the acute period; anti-TPO antibodies reflect inflammation in the chronic period.^{21,22} Therefore, it has been shown in many studies that anti-TPO is correlated with parenchymal stiffness in elastography.^{12,23} However, these autoantibodies may be high in SAT.²⁴ In our study, anti-TPO values in the SAT group were found to be positive at a similar rate to the CAT group. However, anti-Tg antibody levels were higher in the CAT group.

This study has some limitations. The small number of patients in both groups and the absence of histopathological confirmations are among the major limitations. Although SWE is a more standardized technique than other elastographic methods, it is still a practitioner-dependent modality. In our study, we tried to minimize this limitation by performing all measurements by the same radiologist. In some studies, they proved that SWE values in CAT cases increase with the stage, duration, and degree of fibrosis of the disease.^{15,16} Based on this, T3–T4 values will decrease and TSH values will increase in hypofunctional thyroid gland that becomes fibrotic as a result of chronic damage. However, since most of our cases were under hormone replacement therapy, they were euthyroid. Therefore, the relationship between SWE values and thyroid function tests was not evaluated in our study. The important difference of our study compared to other similar studies is that we evaluated it as a whole with its laboratory, grayscale, and elastographic features including V_{sd} .

In conclusion, although clinical, laboratory, and radiological boundaries cannot be clearly distinguished from each other in SAT–CAT distinction, elastographic features can be helpful. It

supports the diagnosis of SAT, especially in the presence of heterogeneous and hypovascular areas with elastographically higher V_{mean} and V_{sd} values, especially if V_{sd} is above 0.4.

Ethics Committee Approval: Ethics committee approval was received for this study from the ethics committee of Acibadem Mehmet Ali Aydınlar University (Date: June 9, 2021; Number: 2021-10/08).

Informed Consent: Informed consent was obtained from all individual participants included in the study.

Peer-review: Externally peer-reviewed.

Author Contributions: Concept – D.E.T.Ş., D.Y.; Design – D.E.T.Ş., D.Y.; Supervision – D.Y.; Resources – D.E.T.Ş.; Materials – D.E.T.Ş.; Data Collection and/or Processing – D.E.T.Ş.; Analysis and/or Interpretation – D.E.T.Ş.; Literature Research – D.E.T.Ş.; Writing Manuscript – D.E.T.Ş.; Critical Review – D.Y.

Conflict of Interest: The authors have no conflict of interest to declare.

Financial Disclosure: The authors declared that this study has received no financial support.

References

- Omori N, Omori K, Takano K. Association of the ultrasonographic findings of subacute thyroiditis with thyroid pain and laboratory findings. *Endocr J*. 2008;55(3):583-588. [\[CrossRef\]](#)
- Park SY, Kim EK, Kim MJ, et al. Ultrasonographic characteristics of subacute granulomatous thyroiditis. *Korean J Radiol*. 2006;7(4):229-234. [\[CrossRef\]](#)
- Hekimoglu K, Yildirim Donmez F, Arslan S, et al. The role of shear wave elastography in the diagnosis of chronic autoimmune thyroiditis. *Med Ultrason*. 2015;17(3):322-326. [\[CrossRef\]](#)
- Jones MR, Mohamed H, Catlin J, et al. The presentation of lymph nodes in Hashimoto's thyroiditis on ultrasound. *Gland Surg*. 2015;4(4):301-306. [\[CrossRef\]](#)
- Saravanan P, Dayan CM. Thyroid autoantibodies. *Endocrinol Metab Clin North Am*. 2001;30(2):315-337, viii. [\[CrossRef\]](#)
- Ruchala M, Szczepanek-Parulska E, Zybek A, et al. The role of sonoelastography in acute, subacute and chronic thyroiditis: a novel application of the method. *Eur J Endocrinol*. 2012;166(3):425-432. [\[CrossRef\]](#)
- Frates MC, Marqusee E, Benson CB, Alexander EK. Subacute granulomatous (de Quervain) thyroiditis: grayscale and color Doppler sonographic characteristics. *J Ultrasound Med*. 2013;32(3):505-511. [\[CrossRef\]](#)
- Caturegli P, De Remigis A, Rose NR. Hashimoto thyroiditis: clinical and diagnostic criteria. *Autoimmun Rev*. 2014;13(4-5):391-397. [\[CrossRef\]](#)
- Park M, Park SH, Kim EK, et al. Heterogeneous echogenicity of the underlying thyroid parenchyma: how does this affect the analysis of a thyroid nodule? *BMC Cancer*. 2013;13:550. [\[CrossRef\]](#)
- Vita R, Di Bari F, Perelli S, Capodicasa G, Benvenga S. Thyroid vascularization is an important ultrasonographic parameter in untreated Graves' disease patients. *J Clin Transl Endocrinol*. 2019;15:65-69. [\[CrossRef\]](#)
- Fukuhara T, Matsuda E, Izawa S, Fujiwara K, Kitano H. Utility of shear wave elastography for diagnosing chronic autoimmune thyroiditis. *J Thyroid Res*. 2015;2015:164548. [\[CrossRef\]](#)
- Sporea I, Vlad M, Bota S, et al. Thyroid stiffness assessment by acoustic radiation force impulse elastography (ARFI). *Ultraschall Med*. 2011;32(3):281-285. [\[CrossRef\]](#)
- Menzilcioglu MS, Duymus M, Gungor G, et al. The value of real-time ultrasound elastography in chronic autoimmune thyroiditis. *Br J Radiol*. 2014;87(1044):20140604. [\[CrossRef\]](#)
- Yang Z, Zhang H, Wang K, Cui G, Fu F. Assessment of diffuse thyroid disease by strain ratio in ultrasound elastography. *Ultrasound Med Biol*. 2015;41(11):2884-2889. [\[CrossRef\]](#)
- Cosgrove D, Barr R, Bojunga J, et al. WFUMB guidelines and recommendations on the clinical use of ultrasound elastography: part 4. Thyroid. *Ultrasound Med Biol*. 2017;43(1):4-26. [\[CrossRef\]](#)

16. Kara T, Ateş F, Durmaz MS, et al. Assessment of thyroid gland elasticity with shear-wave elastography in Hashimoto's thyroiditis patients. *J Ultrasound*. 2020;23(4):543-551. [\[CrossRef\]](#)
17. Liu J, Zhang Y, Ji Y, Wan Q, Dun G. The value of shear wave elastography in diffuse thyroid disease. *Clin Imaging*. 2018;49:187-192. [\[CrossRef\]](#)
18. Ayca Ata Korkmaz H, Baki C, Kose M, Yaldiz Cobanoglu B. Value of real-time and strain ratio elastography in differential diagnosis of Graves' disease and subacute and Hashimoto's thyroiditis. *Iran J Radiol*. 2017;14(4):e22019. [\[CrossRef\]](#)
19. Fukuhara T, Matsuda E, Endo Y, et al. Impact of fibrotic tissue on shear wave velocity in thyroid: an *ex vivo* study with fresh thyroid specimens. *BioMed Res Int*. 2015;2015:1-5. [\[CrossRef\]](#)
20. Siriwardhane T, Krishna K, Ranganathan V, et al. Significance of anti-TPO as an early predictive marker in thyroid disease. *Autoimmune Dis*. 2019;2019:1684074. [\[CrossRef\]](#)
21. Pearce EN, Farwell AP, Braverman LE. Thyroiditis. *N Engl J Med*. 2003;348(26):2646-2655. [\[CrossRef\]](#)
22. Schiemann U, Avenhaus W, Konturek J, et al. Relationship of clinical features and laboratory parameters to thyroid echogenicity measured by standardized grey scale ultrasonography in patients with Hashimoto's thyroiditis. *Diagn Med Technol*. 2003;9(4):49-53.
23. Magri F, Chytiris S, Capelli V, et al. Shear wave elastography in the diagnosis of thyroid nodules: feasibility in the case of coexistent chronic autoimmune Hashimoto's thyroiditis. *Clin Endocrinol*. 2012;76(1):137-141. [\[CrossRef\]](#)
24. Sencar ME, Çalapkulu M, Sakız D, et al. Frequency of thyroid antibodies at the diagnosis of subacute thyroiditis. *Turk J Endocrinol Metab*. 2020;24(2):144-148. [\[CrossRef\]](#)