

# Comparing the Efficacy of the Knotless Suture Anchor Technique in Bony and Soft Tissue Bankart Lesions: A Cohort Study on Shoulder Instability Patients

Yiğit Kültür<sup>1</sup>, Mehmed Nuri Tütüncü<sup>2</sup>, Mahmut Kürşat Özşahin<sup>3</sup>, Nuri Aydın<sup>3</sup>

<sup>1</sup>Department of Orthopedics and Traumatology, İstanbul Yeni Yüzyıl University, Gaziosmanpaşa Hospital, İstanbul, Türkiye

<sup>2</sup>Department of Orthopedics and Traumatology, Medeniyet University, Göztepe Training and Research Hospital, İstanbul, Türkiye

<sup>3</sup>Department of Orthopedics and Traumatology, İstanbul University-Cerrahpaşa, Cerrahpaşa Faculty of Medicine, İstanbul, Türkiye

**Cite this article as:** Kültür Y, Nuri Tütüncü M, Özşahin MK, Aydın N. Comparing the efficacy of the knotless suture anchor technique in bony and soft tissue Bankart lesions: A cohort study on shoulder instability patients. *Cerrahpaşa Med J.* 2024;48(2):112-118.

## Abstract

**Objective:** In this study, patients who received small- to medium-sized bony Bankart repair using the same surgical method as arthroscopic soft tissue Bankart repair also had their functional results, patient-reported outcomes, and shoulder stability compared. We predict that patients with bony and soft tissue Bankart lesions will respond as well to arthroscopic therapy with suture anchors administered using the same approach.

**Methods:** A retrospective analysis was performed on 71 individuals who underwent arthroscopic Bankart repair between 2013 and 2018. These patients were divided into 2 groups: bony Bankart (group 1, consisting of 42 patients) and classic Bankart (group 2, comprising 29 patients). Glenoid defects and bone fragment sizes were determined independently by 2 observers. The evaluation included the assessment of Constant and Rowe scores, recurrence rates, and levels of satisfaction.

**Results:** In group 1, the preoperative Rowe and Constant scores averaged 44.5 (ranging from 15 to 95, SD  $\pm$  19) and 71.7 (ranging from 36 to 96, SD  $\pm$  16.1), respectively. Following the procedure, postoperative Rowe and Constant scores increased to 86.1 (SD  $\pm$  23.6) and 91.3 (ranging from 55 to 100, SD  $\pm$  11.01), respectively. For group 2, postoperative Constant and Rowe scores ranged from 90.4 to 86.3 (SD  $\pm$  10.8 and SD  $\pm$  21.4, respectively), with preoperative scores ranging from 78.9 to 44.4 (SD  $\pm$  13.3 and SD  $\pm$  14.8, respectively). Importantly, there were no statistically significant differences between the preoperative and postoperative Constant and Rowe scores in either group ( $P > .05$ ). In terms of postoperative recurrence, no notable distinctions were observed between the groups ( $P > .05$ ), with 11.9% of patients in group 1 and 13.8% in group 2 experiencing recurrence. After surgery, 9.5% of patients in group 1 and 3.4% in group 2 expressed dissatisfaction, with no statistically significant differences observed ( $P > .05$ ).

**Conclusion:** Comparable results were noted for patients with small-to-medium-sized bony Bankart lesions and classic Bankart lesions when employing identical surgical techniques. Despite the more advanced nature of bony Bankart lesions, similar outcomes were achieved using the same surgical approach as for classic Bankart lesions.

**Level of Evidence:** Level 3 retrospective cohort study

**Keywords:** Arthroscopic bankart repair, traumatic shoulder instability, bony bankart, classic bankart, shoulder dislocation

## Introduction

Shoulder instability is a common issue among younger individuals, often requiring surgical intervention to address the lesion, typically using open procedures with or without capsular shift.<sup>1,2</sup> Suture anchors have become a standard therapeutic approach for labrum repair, especially in patients without significant bone loss or fragments.<sup>3-5</sup> However, about 30% of cases may present with anterior-inferior glenoid fractures or bony Bankart lesions.<sup>6,7</sup> It is recommended to employ a combined transglenoid and suture anchor technique for patients with bony Bankart lesions smaller than 25%, bone fragment lengths of 10-20 mm, and fragment widths shorter than 6 mm. In 1 study, successful outcomes were

reported in arthroscopic Bankart repair for patients with bony Bankart lesions smaller than 25%, particularly if surgery was performed within 3 months of trauma. However, for lesions larger than 25%, bone block procedures (such as Latarjet, iliac crest, allograft, or J graft) were recommended.<sup>8-10</sup>

To date, no study in the literature has compared small- to medium-sized bony Bankart lesions with soft tissue Bankart lesions. This study aims to investigate whether there are any differences in surgical outcomes when employing the same technique with knotless suture anchors between these 2 groups. The hypothesis of the study is that bone-to-bone fusion may contribute to better clinical outcomes in patients with bony Bankart lesions compared to those undergoing soft tissue Bankart repairs.

## Methods

Following the guidelines outlined by national and institutional research committees, as well as the 1964 Helsinki Declaration and its subsequent updates, this study was conducted with strict adherence to ethical standards governing research involving human subjects. No experiments involving animals were conducted as part of this study. Informed consent was obtained from all participants enrolled in the research.

**Received:** November 7, 2023 **Revision Requested:** January 5, 2024

**Last Revision Received:** February 19, 2024 **Accepted:** April 14, 2024

**Publication Date:** July 10, 2024

**Corresponding author:** Yiğit Kültür, Department of Orthopedics and Traumatology, İstanbul Yeni Yüzyıl University, Gaziosmanpaşa Hospital, İstanbul, Türkiye

**e-mail:** yigitkulturr@hotmail.com

**DOI:** 10.5152/cjm.2024.23115

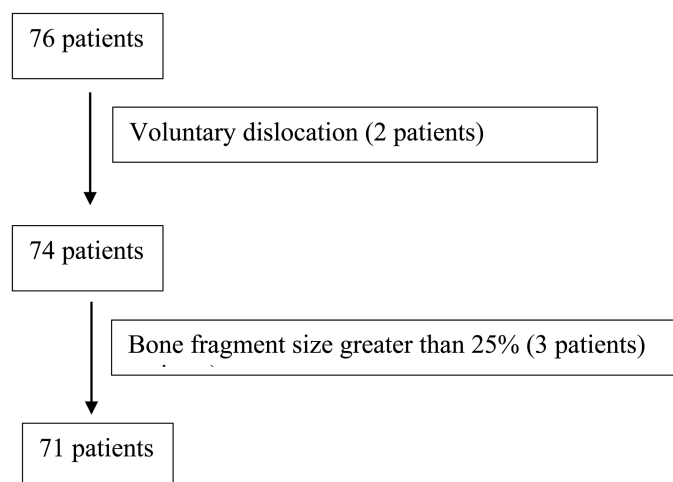


After receiving approval from the İstanbul University Cerrahpaşa, Cerrahpaşa Faculty of Medicine (Approval no: 3910, Date: June 5, 2018), a total of 79 patients who underwent arthroscopic Bankart repair for traumatic shoulder instability between 2013 and 2018 were included in the study. Inclusion criteria consisted of a history of traumatic shoulder instability, positive results on the apprehension test during examination, identification of a glenoid defect and Bankart lesion on magnetic resonance imaging (MRI), and a bone fragment size of less than 25% in cases where a glenoid defect and bone fragment were present. Exclusion criteria encompassed a history of rotator cuff tears in the same shoulder, off-track Hill-Sachs lesions, voluntary dislocations, posterior or multidirectional instability, bone fragment size greater than 25%, neurovascular deficit, active joint or systemic infection, significant muscle paralysis, and patients deemed medically unfit for surgery (Figure 1). Generalized joint laxity was assessed using the Beighton test.<sup>11</sup> After excluding 8 individuals, who either had intentional dislocations or off-track Hill-Sachs lesions, 71 patients were included in the study.

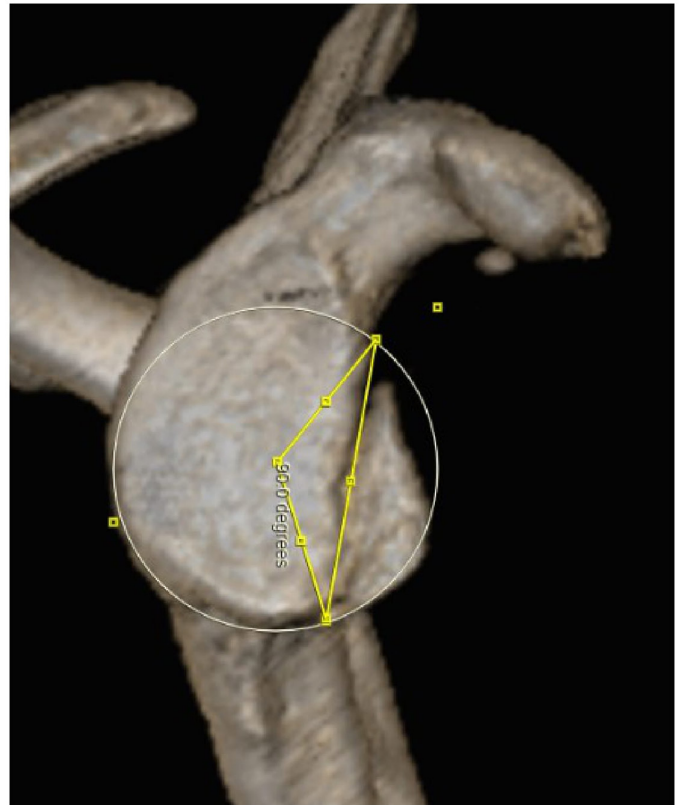
Patients were stratified into 2 groups based on preoperative computed tomography (CT) scan images. The presence of fracture fragments in the anteroinferior glenoid classified patients into the bony Bankart group (group 1), while those without visible fracture fragments were categorized into the traditional Bankart group (group 2). The percentage of glenoid defect was calculated using the Dumont et al.<sup>12</sup> technique, while the extent of the bone fragment was determined by calculating its percentage relative to the length of the glenoid rim (Figure 2). After calculating the angle between the 2 lines, the calculation is made using the bone defect percentage template.

The extent of the bone fragment was determined by calculating its percentage relative to the length of the glenoid rim.<sup>13</sup> This measurement was taken from the clearest joint surface to the maximum length of the bone fragment (Figure 3). Bone fragment sizes falling within the range of 0%-12.5% were categorized as small, while those within the range of 12.5%-25% were classified as medium.<sup>14</sup>

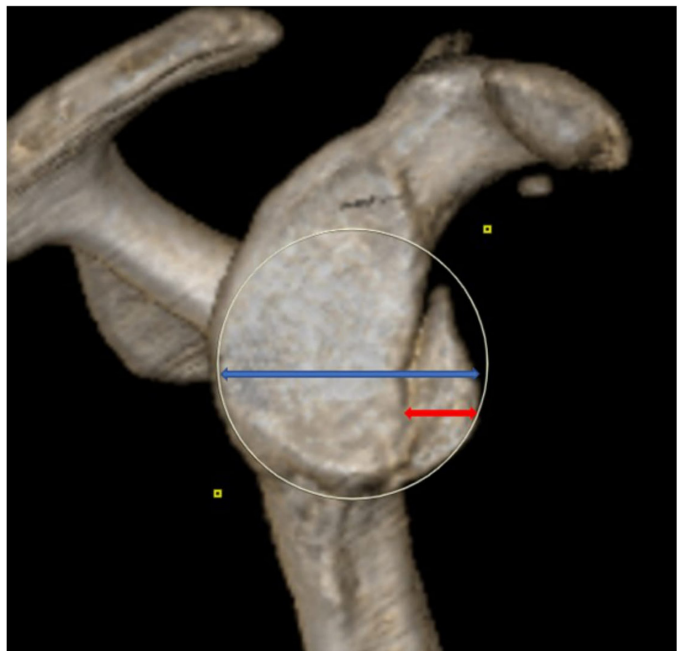
Preoperative and postoperative evaluations using Constant and Rowe scores were conducted at 3, 6, and 12 months, as well as at the patients' last follow-up appointments, which occurred on average 37.23 months (SD  $\pm$  15.27) postoperatively. Radiological



**Figure 1.** Flowchart of exclusion of patients.



**Figure 2.** Measurement of glenoid bone loss. Straight lines are drawn from the center of the glenoid circle to the superior and inferior of the defect and the angle between the 2 lines is calculated.



**Figure 3.** Measurement of bone fragment size. The extent of the bone fragment (red arrow) was calculated as a percentage of the glenoid rim length (blue arrow).

assessments were performed using anteroposterior shoulder, true AP shoulder, axillary and scapular Y views, with CT and MR images evaluated by 2 observers before surgery. Postoperative evaluations were conducted by a blinded surgeon independent of the surgical technique employed, minimizing bias in the assessment process.

### Surgical Technique

During the surgical procedure under general anesthesia, patients were positioned in a beach chair. Important anatomical landmarks such as the acromion, coracoid process, distal clavicle, and acromioclavicular joint were identified, and arthroscopy began through a standard posterior portal. Diagnostic arthroscopy via this portal allowed for assessment of various structures including the labrum, capsule, rotator cuff, biceps tendon, and humeral head. Additional portals were created if Bankart lesions were observed, with different-sized cannulas inserted accordingly. Bankart lesions were then addressed, mobilizing them from the glenoid and preparing the glenoid surface for repair if necessary. Bone fragments, if present, underwent similar treatment. Suturing techniques were employed, with nonabsorbable sutures passed through the labrum or around bone fragments as needed.<sup>15</sup> Suture anchors were carefully placed, ensuring proper tension and anatomical reduction, especially for smaller bone fragments. Knotless suture anchors were consistently utilized in the procedures.

### Postoperative Rehabilitation

Patients were released from the hospital either on the surgery day or the subsequent day. Both groups adhered to standard postoperative recovery plans. Every individual received a shoulder–arm sling for a 3-week duration post surgery, and pendulum exercises were initiated the day after the procedure. Range of motion activities started in the fourth week, with active strengthening exercises commencing in the eighth week. Patients were cautioned against engaging in sports activities until 4 months post surgery.

### Statistical Analysis

The Number Cruncher Statistical System 2007 program, which is based in Kaysville, Utah, USA, was used to perform statistical analyses. Descriptive statistical methods, including mean, standard deviation, median, frequency, percentage, minimum, and maximum values, were used to analyze the research data. Both graphical analysis and the Shapiro–Wilk test were used to evaluate the normality of quantitative data. The Student's *t*-test was used to compare 2 groups on regularly distributed quantitative data, while the Mann–Whitney *U*-test was used to compare non-normally distributed variables. Fisher's exact test and the Fisher–Freeman–Halton exact test were used while dealing with qualitative data. A *P*-value of less than .05 was deemed highly important.

### Results

42 individuals, 37 men and 5 females, made up group 1. Their average age was 26.8 years (range: 15 to 55, SD  $\pm$  8.11), and their mean follow-up period was 34.5 months (range: 13 to 67, SD  $\pm$  13.57). Group 2 consisted of 29 patients, 27 of whom were male and 2 of whom were female. The patients' mean age was 26.5 years (SD  $\pm$  8.29), and their mean follow-up period was 41.1 months (SD  $\pm$  16.93), with a range of 15 to 40. Group 2 comprised 5 pro athletes: 3 footballers, 1 kickboxer, along with a judo athlete. Group 1 consisted of 1 professional wrestler.

Age, sex, Bankart type, dominant side, operated side, time between the first dislocation and surgery, preoperative and postoperative dislocation rate, number of anchors/dislocation rate,

**Table 1.** Evaluation of Parameters in all Patients

Age	Minimum–maximum (median)	15-55 (26)
	Mean $\pm$ SD	26.73 $\pm$ 8.13
Gender	Female, n (%)	7 (9.9%)
	Male, n (%)	64 (90.1%)
Bankart type	Bony Bankart	42 (59.2%)
	Classic Bankart	29 (40.8%)
Dominant side	Right	47 (66.2%)
	Left	24 (33.8%)
Operated side	Right	47 (66.2%)
	Left	24 (33.8%)
Preoperative dislocation rate	1 dislocation	7 (9.9%)
	1-10 dislocation	32 (45.1%)
	10-20 dislocation	14 (19.7%)
	>20 dislocation	18 (25.4%)
Number of anchors used	2	35 (49.3%)
	3	35 (49.3%)
	4	1 (1.4%)
Satisfaction with surgery	Satisfied	66 (93.0%)
	Not satisfied	5 (7.0%)
Postoperative dislocation	–	62 (87.3%)
	+	9 (12.7%)
Follow-up time (months)	Minimum–maximum (median)	13-69 (33)
	Mean $\pm$ SD	37.23 $\pm$ 15.27

satisfaction with surgery, postoperative scores, and follow-up times are shown in Tables 1, 2, and 3.

Age, distribution of sexes, preoperative/postoperative dislocation rates, and surgical satisfaction did not significantly differ across the groups (*P* > .05). There was no statistically meaningful variation among the groups (*P* > .05), with the total postoperative dislocation rate being 12.7%, with 11.9% of those surveyed in group 1 and 13.8% in group 2 having postoperative dislocation.

A total of 29 people had no glenoid defects, and the mean preoperative glenoid defect size was 5.25% (SD  $\pm$  5.24), with a range of 0 to 15.6. The mean defect size among the 44 individuals with bone defects was 8.48% (SD  $\pm$  4.08), with a range of 1.25 to 15.6. Group 1 showed an average proportion of bone Bankart fragment size of 9.16% (SD  $\pm$  3.86), with 5 patients having medium-sized fragments and 37 patients possessing small-sized fragments. The range of fragment sizes was 2 to 22.

After arthroscopic Bankart repair, both groups showed a substantial recovery in preoperative and postoperative Constant and

**Table 2.** Evaluation of Parameters According to Groups

		Bankart Type		Test Value <i>P</i>
		Bony (n = 42)	Classic (n = 29)	
Age	Minimum–maximum	15-55	15-40	<i>t</i> : 0.327
	(Median)	(26)	(25)	
	Mean ± SD	26.85 ± 8.11	26.55 ± 8.29	.744 <sup>b</sup>
Gender	Female	5 (11.9%)	2 (6.9%)	$\chi^2$ : 0.484
	Male	37 (88.1%)	27 (93.1%)	.692 <sup>a</sup>
Dominant side	Right	40 (95.2%)	25 (86.2%)	
	Left	2 (4.8%)	4 (13.8%)	
Operated side	Right	31 (73.8%)	16 (55.2%)	
	Left	11 (26.2%)	13 (44.8%)	
Preoperative dislocation rate	1	2 (4.8%)	5 (17.2%)	$\chi^2$ : 3.440
	1-10	19 (45.2%)	13 (44.8%)	.335 <sup>d</sup>
	10-20	10 (23.8%)	4 (13.8%)	
	>20	11 (26.2%)	7 (24.1%)	
Time between first dislocation and surgery (months)	Minimum–maximum	1-216 (48)	0.5-221	
	(Median)	(48)	(48)	
	Mean ± SD	59.68 ± 51.46	60.43 ± 61.51	
Postoperative dislocation	–	37 (88.1%)	25 (86.2%)	$\chi^2$ : 0.055
	+	5 (11.9%)	4 (13.8%)	1.000 <sup>a</sup>
Satisfaction with surgery	Satisfied	38 (90.5%)	28 (96.6%)	$\chi^2$ : 0.967
	Not satisfied	4 (9.5%)	1 (3.4%)	.642 <sup>a</sup>
Follow-up time (months)	Minimum–maximum	13-67	13-69	
	(Median)	(32)	(45)	
	Mean ± SD	34.52 ± 13.57	41.14 ± 16.93	
The number of suture anchors used and dislocation rate	2 anchors	2 (8.7%)	0 (0.0%)	<i>Z</i> : –1.709 .088 <sup>c</sup>
	3 anchors	2 (11.1%)	4 (23.5%)	
	4 anchors	1 (100.0)	0 (0.0%)	

<sup>a</sup>Fisher's exact test.<sup>b</sup>Student's *t*-test.<sup>c</sup>Mann–Whitney *U*-test.<sup>d</sup>Wilcoxon signed-rank test.

Rowe ratings ( $P = .001$ ). But there was no discernible difference in the 2 groups' levels of improvement ( $P > .05$ ).

There was no discernible difference between groups 1 and 2 in terms of the number of suture anchors or the rate of postoperative dislocations ( $P > .05$ ).

The reasons for postoperative dislocation, the timing of the dislocation, the number of postoperative dislocations, preoperative dislocations, the amount of time that passed between the initial dislocation and surgery, and the fragment size of redischarged bony Bankart patients were among the many parameters that were analyzed for both groups (Table 4).

## Discussion

The primary findings of this study indicate that there are similar outcomes between classic Bankart repair and bony Bankart repair when performed by the same surgeon using the same surgical technique. It has been observed that despite being a more advanced medical condition than the classic Bankart lesion, similar results are achieved when the same surgical technique is applied in the case of bony Bankart lesions.

There are many studies in the literature about dislocation after arthroscopic Bankart repair. In these studies, the rate of dislocations ranged between 5% and 35%.<sup>16-18</sup> Increased rates of dislocations

**Table 3.** Evaluations of Preoperative and Postoperative Scores According to Groups

		Bankart Type		Test Value
		Bony (n = 42)	Classic (n = 29)	P
Preoperative Rowe	Mean ± SD	44.57 ± 19	44.48 ± 14.84	Z: -0.095 .924 <sup>a</sup>
Postoperative Rowe	Mean ± SD	86.12 ± 23.69	86.38 ± 21.42	Z: -0.261 .794 <sup>a</sup>
	Difference	41.55 ± 29.08	41.90 ± 24.07	Z: -0.053 .958 <sup>a</sup>
	P	<.01	<.01	
Preoperative Constant	Mean ± SD	71.77 ± 16.19	78.97 ± 13.36	Z: -1.844 .065 <sup>a</sup>
Postoperative Constant	Mean ± SD	91.31 ± 11.01	90.41 ± 10.82	Z: -0.443 .658 <sup>a</sup>
	Difference	19.54 ± 20.10	11.45 ± 17.32	Z: -1.709 .088 <sup>a</sup>
	<sup>c</sup> P	<.01	<.01	

<sup>a</sup>Mann-Whitney U-test.

may be associated with increased durations of follow-ups. The dislocation rate observed in our study, 12.7% (group 1: 11.9% and group 2: 13.8%), aligns with rates reported in the literature. Kim et al.<sup>14</sup> compared patients with bony Bankart lesions having small and medium-sized fragments, highlighting the significance of anatomical restoration of the bone fragment, particularly in patients with medium-sized fragments.

Throughout a 14-year monitoring, sportsmen who had arthroscopic Bankart surgery had Constant scores of 96.7 and Rowe scores of 83.4, indicating good long-term clinical results.<sup>19</sup> Comparably, a research by Mousavibaygei et al.<sup>20</sup> with 300 patients revealed that, a year after surgery, the average Rowe score was 97.2 and the average Constant score was 83.6. These results highlight the efficacy of arthroscopic Bankart repair as a therapeutic

approach. Group 2 in our study showed ratings of 90.4 and 86.3, respectively, whereas Constant and Rowe scores were 91.3 and 86.1, respectively, in group 1.

Treatment options for patients with bony Bankart lesions include open reduction screw fixation, arthroscopic screw fixation, and arthroscopic suture anchor fixation.<sup>21</sup> Godin et al.<sup>22</sup> presented the results of 13 patients who underwent arthroscopic suture bridge anchor repair of bony Bankart lesions, with 3 patients experiencing post-surgery instability according to the findings. According to these results, there were findings of instability in 3 patients after surgery. However, the patients did not undergo revision surgery. In the study by Millett et al.,<sup>23</sup> recurrence after surgery was observed in 1 out of 15 patients who underwent bony Bankart repair with the arthroscopic bridge

**Table 4.** Evaluation of Patients with Postoperative Dislocations

	RPOD	TPOD	NDAS	NDOP	PFDS	BFS
Bony Bankart						
Patient 1	Epileptic seizure	2 years	1	~50	11 years	7%
Patient 2	Wrestling	5 months	4	7	4 months	10%
Patient 3	Wearing an athlete	9 months	2	~20	6 years	11%
Patient 4	Simple fall	3 months	1	~20	1 year	9%
Patient 5	Simple fall	6 months	1	>50	7 years	3%
Classic Bankart						
Patient 1	Fell from a height	2 years	1	~20	1 year	Patient 1
Patient 2	Throwing stone	2 years	1	6	5 years	Patient 2
Patient 3	Playing volleyball	6 months	6	1	2 months	Patient 3
Patient 4	Wrestling	5 months	1	~20	1 year	Patient 4

BFS, bone fragment size; NDAS, number of dislocation after surgery; NDOP, number of dislocation occurred preoperatively; PFDS, period between the first dislocation and surgery; RPOD, reason of postoperative dislocation; TPOD, time of postoperative dislocation.

technique. Patient satisfaction was recorded as 10 out of 10 during the last follow-up.

Spiegel et al.<sup>24</sup> conducted a study where bony Bankart lesions were created on 14 glenoids sourced from cadavers, comparing the strength of double-row and single-row repair methods. Their findings indicated that double-row repairs exhibited higher reduction ability and stability. However, randomized clinical trials directly comparing double-row and single-row repairs are scarce in the literature. Consequently, the choice of fixation method should be based on the individual pathology of the patient. Currently, single-row repair remains the prevalent and accepted fixation method.<sup>25</sup> In our study, all patients underwent single-row repair.

The physician felt more at ease and comfortable with knotless anchors; therefore, it was preferred for use in all procedures. There are differing views in the literature about whether knot-tying anchors are better than knotless anchors. Redislocation rates and clinical ratings for knotless and knot-tying anchors were shown to be comparable in a recent research by Shim et al.<sup>26</sup>

In the study by Habermeyer et al.,<sup>27</sup> patients were categorized into 5 subgroups based on the number of preoperative dislocations, with increased degeneration noted in each group as the number of dislocations rose. However, in our study, no statistically significant difference was observed between the bony and classic Bankart groups when patients were compared in terms of the number of preoperative dislocations ( $P > .05$ ).

In our study, no statistical relationship was found between the number of suture anchors used and the rate of dislocations. Some studies have reported a significant increase in dislocations when fewer than 4 suture anchors were used compared to patients on whom 4 or more suture anchors were utilized.<sup>28,29</sup> Witney-Lagen et al.,<sup>30</sup> with a minimum follow-up duration of 4 years, reported dislocation in 2 out of 71 patients (2%) who underwent single suture anchor application using the purse-string technique. Aydin et al.<sup>31</sup> suggested that in cases where the surgeon cannot employ more than 2 anchors, an additional capsular shift technique may be applied. However, they noted that the recurrence rate in the group with 2 anchors and capsular shift was higher than that in the group with 3 anchors.

One strength of our study is that all surgeries were performed by a single surgeon, and both preoperative and postoperative clinical evaluations were conducted by the same surgeon. Additionally, uniform techniques and materials were employed across all cases. To our knowledge, no study has compared patients with small- to medium-sized bony Bankart lesions and classic Bankart patients without any bone fragments.

However, our study had limitations, including a small number of patients. The groups were not homogeneous due to variations in the number of shoulder dislocations prior to surgery. Furthermore, postoperative CT scans were not performed on patients, so information regarding the union rate of repaired bony Bankart lesions or fragment resorption was unavailable.

## Conclusion

Our study findings revealed no discernible disparity regarding pre/postoperative scores and postoperative dislocation rates between patients diagnosed with bony Bankart lesions and those with classic Bankart conditions. It has been observed that despite the bony Bankart lesion being a more advanced medical condition, similar outcomes are achieved when the same surgical technique is applied as in the case of the classic Bankart lesion.

**Ethics Committee Approval:** Ethics committee approval was received for this study from the Istanbul University Cerrahpaşa, Cerrahpaşa Faculty of Medicine (Approval no: 3910, Date: June 5, 2018).

**Informed Consent:** Written informed consent was obtained from patients who participated in this study.

**Peer-review:** Externally peer-reviewed.

**Author Contributions:** Concept – Y.K., N.A.; Design – Y.K., N.A.; Supervision – M.K.O., M.N.E.; Resources – Y.K., N.A., M.K.O., M.N.E.; Materials – Y.K., N.A., M.K.O., M.N.E.; Data Collection and/or Processing – Y.K., M.N.E.; Analysis and/or Interpretation – Y.K., N.A., M.K.O., M.N.E.; Literature Search – Y.K., M.N.E.; Writing Manuscript – Y.K., N.A.; Critical Review – Y.K., N.A.

**Declaration of Interests:** The authors have no conflict of interest to declare.

**Funding:** The authors declared that this study has received no financial support.

## References

- Mahiroğullari M, Özkan H, Akyüz M, Uğraş AA, Güney A, Kuşkucu M. Comparison between the results of open and arthroscopic repair of isolated traumatic anterior instability of the shoulder. *Acta Orthop Traumatol Turc.* 2010;44(3):180-185. [\[CrossRef\]](#)
- Carlson Strother CR, McLaughlin RJ, Krych AJ, Sanchez-Sotelo J, Camp CL. Open shoulder stabilization for instability: anterior Labral repair with capsular shift. *Arthrosc Tech.* 2019;8(7):e749-e754. [\[CrossRef\]](#)
- Demirhan M, Esenyele CZ. Arthroscopic treatment of traumatic anterior glenohumeral instability. *Acta Orthop Traumatol Turc.* 2005;39(suppl 1):57-74.
- Ozbydar MU, Tonbul M, Baca E, Yalaman O. Arthroscopic treatment of anterior-inferior shoulder instability. *Acta Orthop Traumatol Turc.* 2007;41(2):120-126.
- Plath JE, Feucht MJ, Bangoj R, Martetschläger F, Wörtler K. Arthroscopic suture anchor fixation of Bony Bankart lesions: clinical Outcome, magnetic resonance imaging results, and return to sports. *Arthrosc J Arthrosc Relat Surg.* 2015;31(8):1472-1481. [\[CrossRef\]](#)
- Gupta AK, McCormick FM, Abrams GD, et al. Arthroscopic Bony Bankart fixation using a Modified Sugaya technique. *Arthrosc Tech.* 2013;2(3):e251-e255. [\[CrossRef\]](#)
- Kim SJ, Kim TW, Moon HK, Chang WH. A combined transglenoid and suture anchor technique for Bony Bankart lesions. *Knee Surg Sports Traumatol Arthrosc.* 2009;17(12):1443-1446. [\[CrossRef\]](#)
- Moroder P, Schulz E, Wierer G, et al. Neer Award 2019: Latarjet procedure vs. iliac crest bone graft transfer for treatment of anterior shoulder instability with glenoid bone loss: a prospective randomized trial. *J Shoulder Elbow Surg.* 2019;28(7):1298-1307. [\[CrossRef\]](#)
- Moya D, Aydin N, Yamamoto N, et al. Current concepts in anterior glenohumeral instability: diagnosis and treatment. *SICOT J.* 2021;7(48):48. [\[CrossRef\]](#)
- Shin SJ, Kim RG, Jeon YS, Kwon TH. Critical value of anterior glenoid bone loss that leads to recurrent glenohumeral instability after arthroscopic Bankart repair. *Am J Sports Med.* 2017;45(9):1975-1981. [\[CrossRef\]](#)
- Smits-engelsman B, Klerks M, Kirby A. Beighton score: A valid measure for generalized hypermobility in children. *J Pediatr.* 2011;158(1):119-123. [\[CrossRef\]](#)
- Dumont GD, Russell RD, Browne MG, Robertson WJ. Area-based determination of bone loss using the glenoid arc angle. *Arthroscopy.* 2012;28(7):1030-1035. [\[CrossRef\]](#)
- Nakagawa S, Mae T, Yoneda K, Kinugasa K, Nakamura H. Influence of glenoid defect size and bone fragment size on the clinical outcome after arthroscopic Bankart repair in male collision/contact athletes. *Am J Sports Med.* 2017;45(9):1967-1974. [\[CrossRef\]](#)
- Kim YK, Cho SH, Son WS, Moon SH. Arthroscopic repair of small and medium-sized bony Bankart lesions. *Am J Sports Med.* 2014;42(1):86-94. [\[CrossRef\]](#)

15. Sugaya H, Moriishi J, Kanisawa I, Tsuchiya A. Arthroscopic osseous Bankart repair for chronic recurrent traumatic anterior glenohumeral instability. *J Bone Joint Surg Am.* 2005;87(8):1752-1760. [\[CrossRef\]](#)
16. van der Linde JA, van Kampen DA, Terwee CB, Dijkman LM, Kleinjan G, Willems WJ. Long-term results after arthroscopic shoulder stabilization using suture anchors: an 8- to 10-year follow-up. *Am J Sports Med.* 2011;39(11):2396-2403. [\[CrossRef\]](#)
17. Blomquist J, Solheim E, Liavaag S, Schroder CP, Espehaug B, Have- lin LI. Shoulder instability surgery in Norway: the first report from a multicenter register, with 1-year follow-up. *Acta Orthop.* 2012;83(2):165-170. [\[CrossRef\]](#)
18. Öztermeli A, Karakuş Ö, Karaman Ö, Sarı AS, Gürer B, Saygı B. Evaluation of factors affecting outcomes in arthroscopic Bankart repair. *J Clin Pract Res.* 2023;45(4):402-408. [\[CrossRef\]](#)
19. Bauer A, Engel G, Huth J, Mauch F. Fourteen years of follow-up after first arthroscopic Bankart repair in athletes: functional outcomes and magnetic resonance imaging findings. *J Shoulder Elbow Surg.* 2023;32(3):546-554. [\[CrossRef\]](#)
20. Mousavibaygei SR, Moein S, Sharifi Razavi D, Haghi F, Karimi Mat- loub R. Evaluating the results of Bankart repair in recurrent traumatic anterior shoulder dislocation. *Int J Burns Trauma.* 2021;11(4):337-343. <https://pubmed.ncbi.nlm.nih.gov/34557337/>.
21. Sugaya H, Moriishi J, Dohi M, Kon Y, Tsuchiya A. Glenoid rim morphology in recurrent anterior glenohumeral instability. *J Bone Joint Surg Am.* 2003;85(5):878-884. [\[CrossRef\]](#)
22. Godin JA, Altintas B, Horan MP, et al. Midterm results of the Bony Bankart Bridge technique for the treatment of Bony Bankart lesions. *Am J Sports Med.* 2019;47(1):158-164. [\[CrossRef\]](#)
23. Millett PJ, Horan MP, Martetschläger F. The Bony Bankart Bridge technique for restoration of anterior shoulder stability. *Am J Sports Med.* 2013;41(3):608-614. [\[CrossRef\]](#)
24. Spiegl UJ, Smith SD, Todd JN, Coatney GA, Wijdicks CA, Millett PJ. Biomechanical comparison of arthroscopic Single and Double-Row repair techniques for acute Bony Bankart lesions. *Am J Sports Med.* 2014;42(8):1939-1946. [\[CrossRef\]](#)
25. DeFroda S, Bokshan S, Stern E, Sullivan K, Owens BD. Arthroscopic Bankart repair for the management of anterior shoulder instability: indications and outcomes. *Curr Rev Musculoskelet Med.* 2017;10(4):442-451. [\[CrossRef\]](#)
26. Shim JW, Jung TW, Kim IS, Yoo JC. Knot-tying versus knotless suture anchors for arthroscopic Bankart repair: A comparative study. *Yonsei Med J.* 2021;62(8):743-749. [\[CrossRef\]](#)
27. Habermeyer P, Gleyze P, Rickert M. Evolution of lesions of the labrum-ligament complex in posttraumatic anterior shoulder instability: A prospective study. *J Shoulder Elbow Surg.* 1999;8(1):66-74. [\[CrossRef\]](#)
28. Shibata H, Gotoh M, Mitsui Y, et al. Risk factors for shoulder re- dislocation after arthroscopic Bankart repair. *J Orthop Surg Res.* 2014;9(1):53. [\[CrossRef\]](#)
29. Boileau P, Villalba M, Henry J-Y, Frederic B, Ahrens P, Neyton L. Risk factors for recurrence of shoulder instability after arthroscopic Bankart repair. *J Bone Jt Surg Am.* 2006;88(8):1755-1763.
30. Witney-Lagen C, Perera N, Rubin S, Venkateswaran B. Fewer anchors achieves successful arthroscopic shoulder stabilization sur- gery: 114 patients with 4 years of follow-up. *J Shoulder Elbow Surg.* 2014;23(3):382-387. [\[CrossRef\]](#)
31. Aydın N, Karaismailoglu B, Harbiyeli E, Ozsahin MK. Can capsular plication compensate the lack of one suture anchor in an arthroscopic three suture anchor Bankart repair? A comparative study. *Acta Orthop Traumatol Turc.* 2019;18:4-9. [\[CrossRef\]](#)