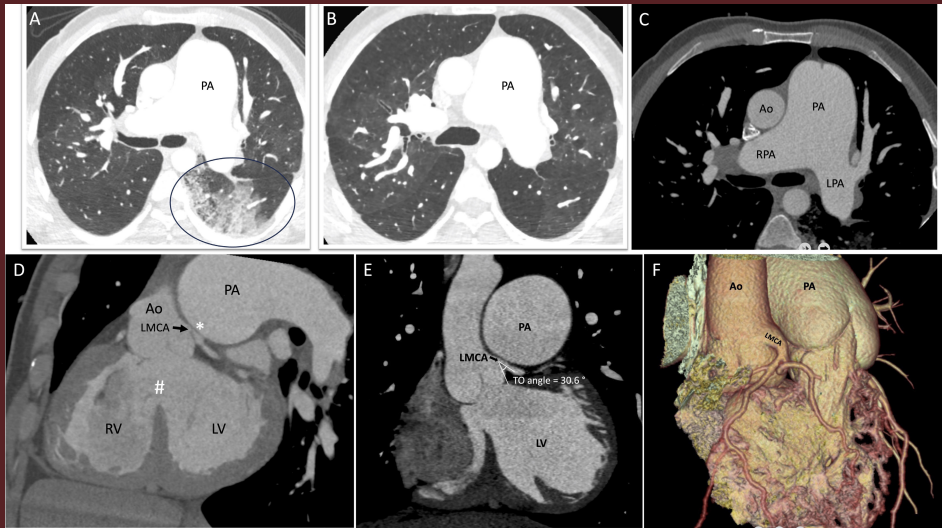


# CERRAHPAŞA MEDICAL JOURNAL



*Coronary Angiogram Revealing Noteworthy Ostial LMCA Stenosis*  
Page: 310

Volume 49

EISSN 2687-1904  
cerahpasamedj.org